



Land O Lakes Equine
 22463 Southshore Dr
 Land O'Lakes, FL 34639-4639
 United States
 (813) 489-9368

GENERATED: 4/11/2023 9:06 AM

Client Information

Erica Smithberger
 5215 Taylor Rd
 Lutz, FL 33556
 (813) 817-3322

Patient Information

<u>Name</u>	Echo	<u>Species</u>	Equine	<u>Weight</u>	850 LBS
<u>Sex</u>	Mare	<u>Breed</u>	Missouri Fox Trotter	<u>Microchip</u>	NONE
<u>Status</u>	Active	<u>DOB</u>	4/15/2010		
<u>Id</u>	686	<u>Age</u>	12 years 11 months		
<u>Color</u>	Black	<u>Tag</u>	NONE		

Weight History

Date	Weight
4/10/2023	850 LBS

Reminders

Description	Due Date
EEE/WEE/Tet/Flu/Rhino/WestNile	4/4/2023
EEE/WEE/Tetanus/WN	10/10/2023
EEE/WEE/Tet/WestNile/Rabies	4/10/2024
Coggins	4/10/2024
Dental Float- Exam/balance	4/10/2024
Wellness Exam	4/10/2024

Medical Chart from 1/1/2000 - 4/10/2023

Service on 4/10/2023

4/10/2023 4:51 PM	Procedure	Trip Fee Zone1	Emily Weaver, D.V.M.
4/10/2023 4:51 PM	Procedure	EEE/WEE/Tetanus/WN/Rabies	Emily Weaver, D.V.M.
4/10/2023 4:51 PM	Lab Result	EIA-D - Coggins Digital -	
No Results			
4/10/2023 4:51 PM	Lab	Coggins Digital	Emily Weaver, D.V.M.
4/10/2023 4:51 PM	Procedure	Dental Float-Exam/balance	Emily Weaver, D.V.M.
4/10/2023 4:51 PM	Inventory Item	Xylazine injection 2 mL	Emily Weaver, D.V.M.
4/10/2023 4:55 PM	Exam	Wellness Exam	Emily Weaver, D.V.M.

Weight 850 LBS (385.5575 KG)
Temperature 99°F By Rectal

Heart Rate 36
 Respiratory Rate 12
 Pulse Quality WNL
 CRT <2 sec
 Mucous Membrane pink
 Hydration WNL
 Body Condition Score 5 - Ideal
 Pain Score 0 - None

Eyes Left Eye Normal Right Eye Normal

Heart and Lungs

heart and lungs auscult WNL, no heart murmur regular rate, and rhythm. Lungs clear.

Skin

WNL

Gastrointestinal GI Auscultation - Normal GI sounds all quadrants Manure - Normal

Hooves

Normal

Genitourinary

Normal

Oral Exam

Routine float performed. Missing 2nd premolar on upper left side.

Musculoskeletal

sound in hand at walk and jog

Nutrition

Parasite Control

4/10/2023 4:55 PM Procedure Wellness Exam Emily Weaver, D.V.M.

Service on 10/4/2022

10/4/2022 3:26 PM Procedure EEE/WEE/Tetanus/Flu/Rhino/WestNile Emily Weaver, D.V.M.

Service on 6/21/2022

6/21/2022 2:14 PM Procedure Recheck Exam Emily Weaver, D.V.M.

left fractured upper pre molar still firmly intact, just trapping food. Recc removal of the fractured molar, ok to wait until back from trip

6/21/2022 2:14 PM Procedure Trip Fee Zone1 Emily Weaver, D.V.M.

Service on 4/26/2022

4/26/2022 12:18 PM Procedure Trip Fee Zone1 Emily Weaver, D.V.M.

4/26/2022 12:18 PM Procedure Digital X-Ray Emily Weaver, D.V.M.

Left upper 2nd pre-molar, lateral portion of Fx tooth still present with root present at proximal edge, with a thin area of hypoechoic line. Keep and eye on the mouth for now, but recommend recheck and possible removal in 6 months

4/26/2022 12:18 PM	Inventory Item	Xylazine injection 2 mL	Emily Weaver, D.V.M.
---------------------------	-----------------------	-------------------------	----------------------

 Service on 4/15/2022

4/15/2022 3:15 PM	Procedure	EEE/WEE/Tetanus/WN/Rabies	Emily Weaver, D.V.M.
--------------------------	------------------	---------------------------	----------------------

4/15/2022 3:15 PM	Procedure	Flu/Rhino	Emily Weaver, D.V.M.
--------------------------	------------------	-----------	----------------------

4/15/2022 3:15 PM	Lab Result	EIA-D - Coggins Digital -	
--------------------------	-------------------	---------------------------	--

No Results

4/15/2022 3:15 PM	Lab	Coggins Digital	Emily Weaver, D.V.M.
--------------------------	------------	-----------------	----------------------

4/15/2022 3:15 PM	Procedure	Dental Float-Exam/balance	Emily Weaver, D.V.M.
--------------------------	------------------	---------------------------	----------------------

Left upper 2nd pre-molar missing, with remnant at lateral edge

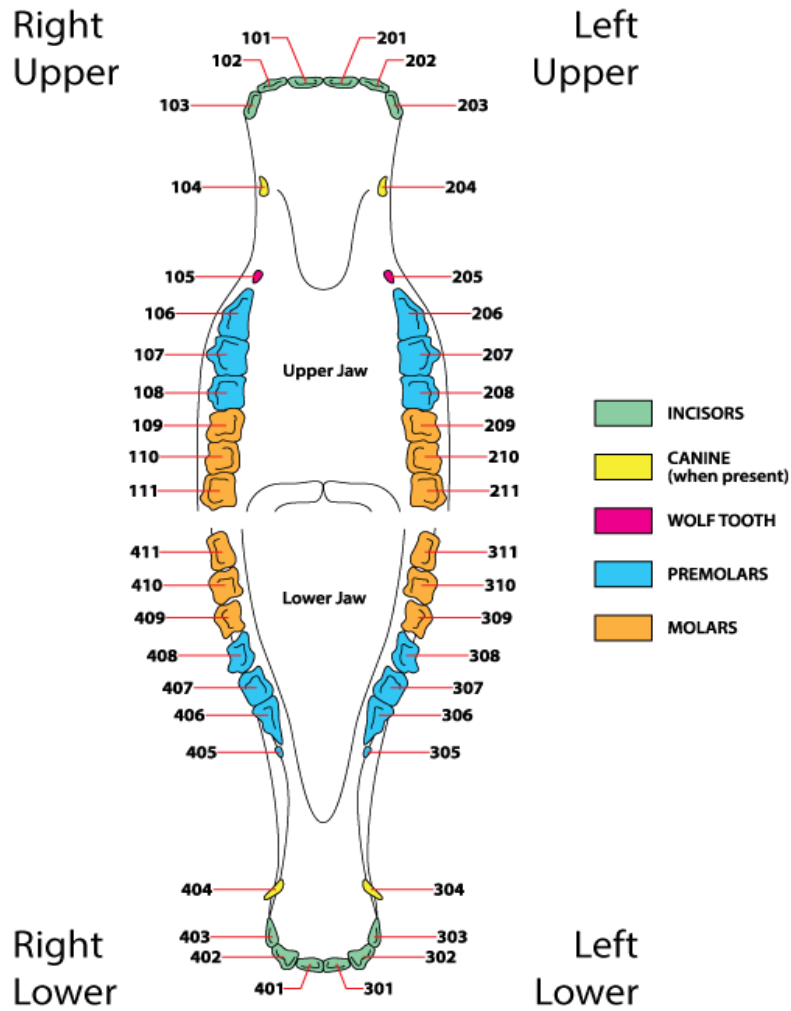
4/15/2022 3:15 PM	Inventory Item	Xylazine injection 2 mL	Emily Weaver, D.V.M.
--------------------------	-----------------------	-------------------------	----------------------

4/15/2022 7:22 PM	Document	Dental Chart - Equine	
--------------------------	-----------------	-----------------------	--

Equine Dental Chart

Monday, April 10, 2023

Client: Erica Smithberger
 Patient Name: **Echo**
 Breed: Missouri Fox Trotter Age: 12 years 11 months



111	110	109	108	107	106	105	104	103	102	101	201	202	203	204	205	206	207	208	209	210	211	
411	410	409	408	407	406	405	404	403	402	401	301	302	303	304	305	306	307	308	309	310	311	

F: Float
 LL: Lingual Lesion
 BL: Buccal Lesion
 H: Hook
 R: Ramp
 PP: Periodontal Pocket
 CWD: Crowding

C: Cap
 S: Step
 FX: Fracture
 W: Wave
 OM: Oral Mass
 ROT: Rotated
 O: Missing Tooth

CA: Caries
 ED: Enamel Defect
 GH: Gingival Hyperplasia
 ST: Stomatitis
 ONF: Oronasal Fistula
 RD: Retained Deciduous

CR: Crown
 X: Extraction
 GI: Gingivitis
 M: Mobility
 PE: Pulp Exposure
 RR: Retained Root

